

Pediatric diaphragm pacing: a thoracoscopic approach

Cathy E. Shin MD FACS FAAP

Assistant Professor of Clinical Surgery
University of Southern California
Keck School of Medicine
Attending Surgeon
Pediatric Surgery
Children's Hospital Los Angeles



Pediatric

- Smaller than Mark's patients
- 5 mm trocars x 3
 - 3mm not necessary
 - Electrode passed thru trocars
 - and don't want to damage electrode
- 5mm 30 degree scope
 - Love to see all angles
 - Esp when my trocar position is suboptimal
 - I hate it when my trocar position is suboptimal

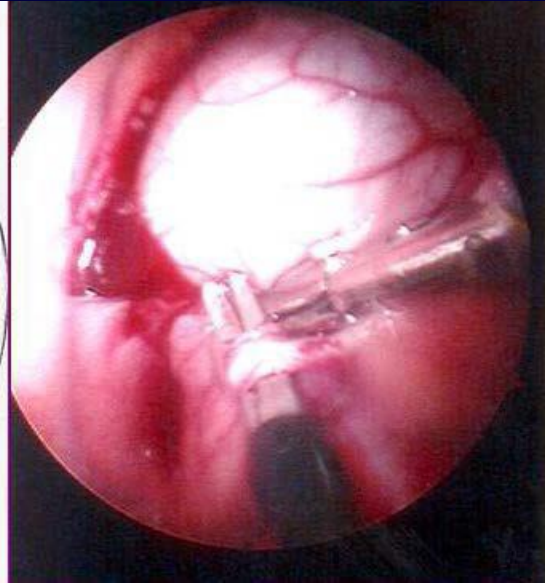
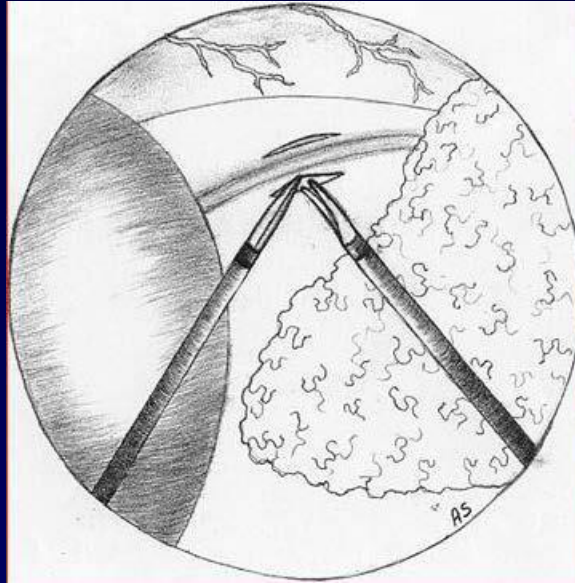
- Single lung ventilation
- Lateral decub position
 - Not full lateral- more soft lateral
 - Otherwise, you are operating
- Veress needle
- Pressures are smaller
 - 5mm Hg CO₂ pressure

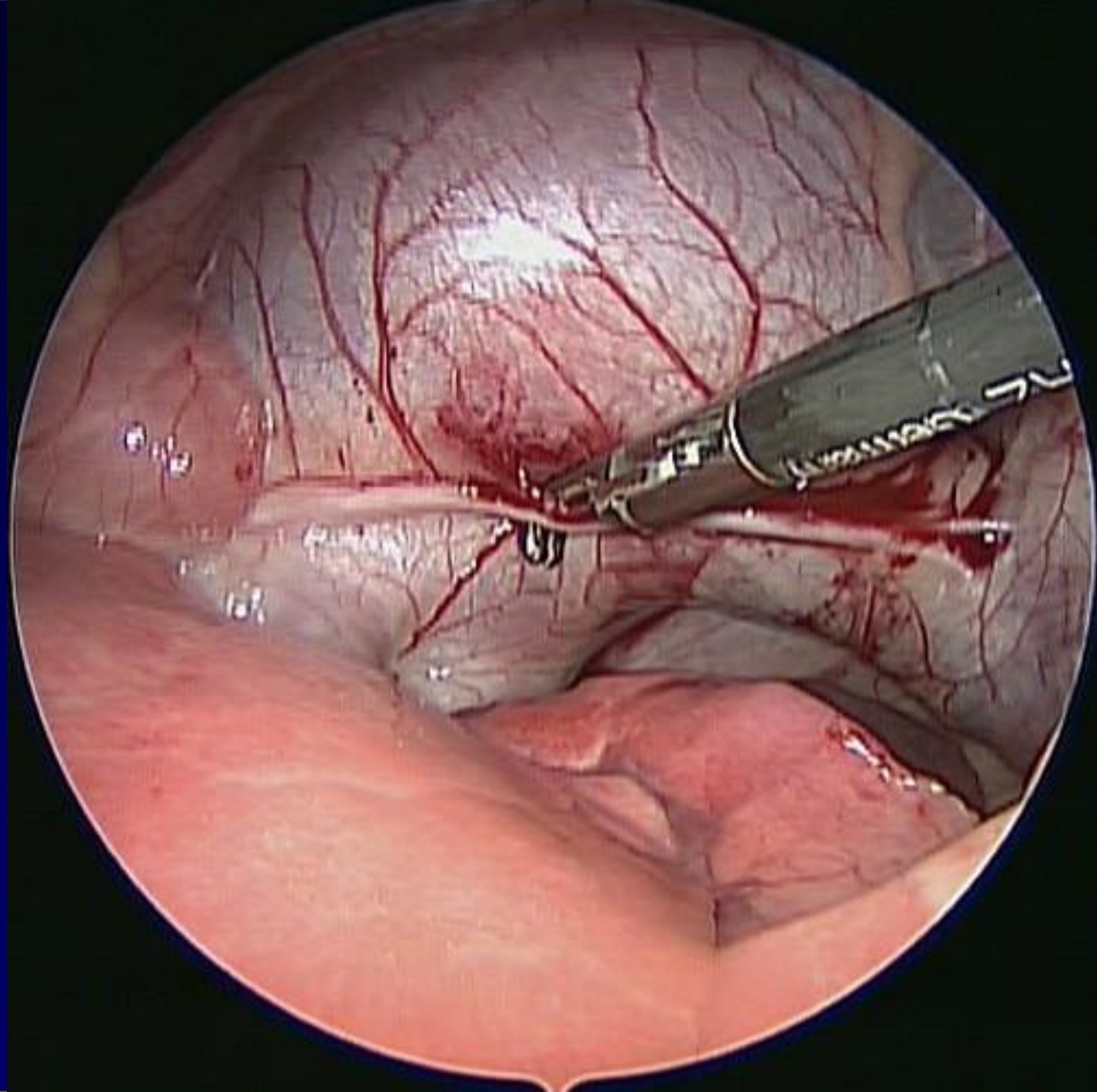
- Patient positioning
- Trocar placement

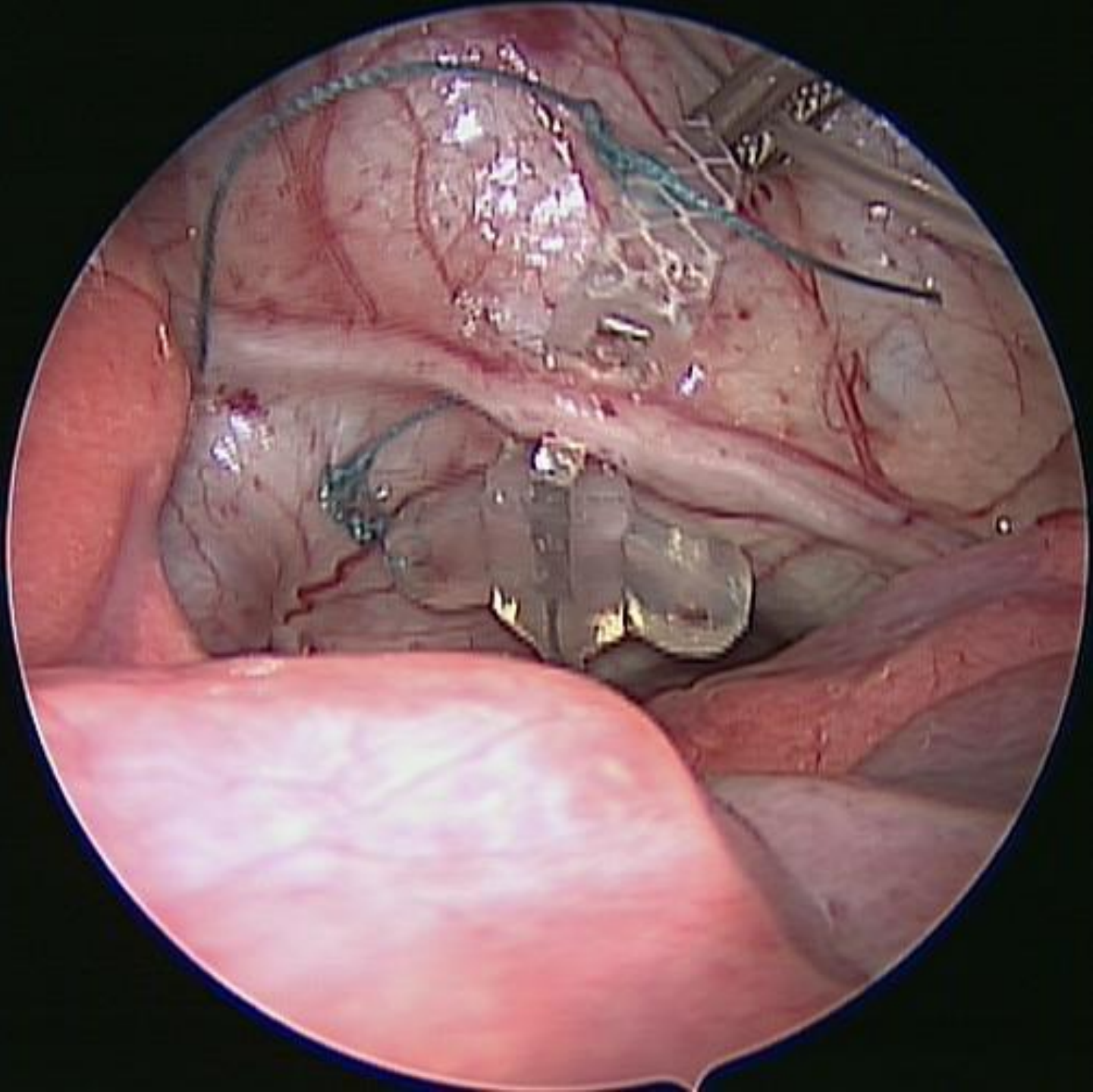
- If right handed- think about needle holder position depending on the location of the lead placement on phrenic

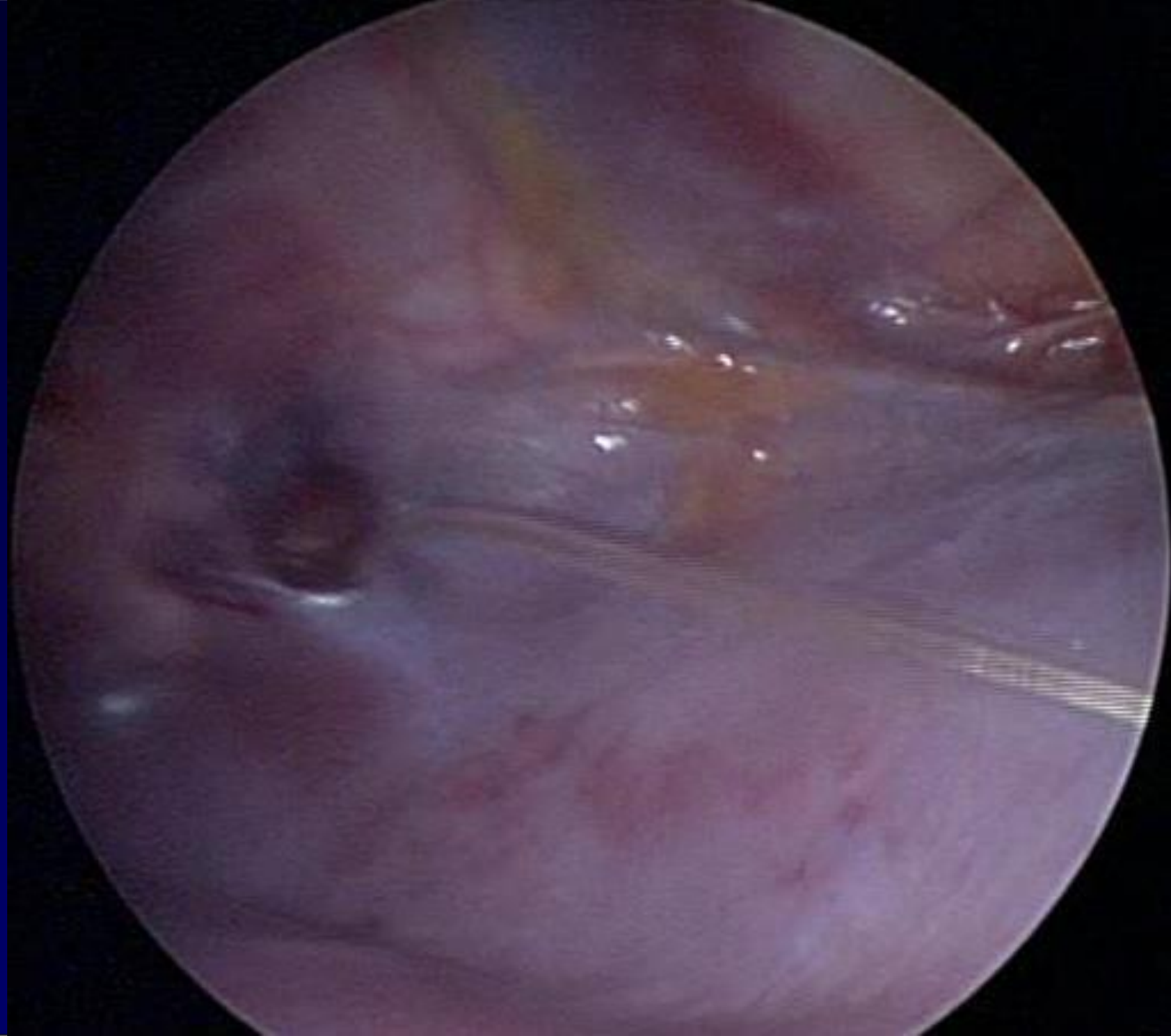
Operative Technique

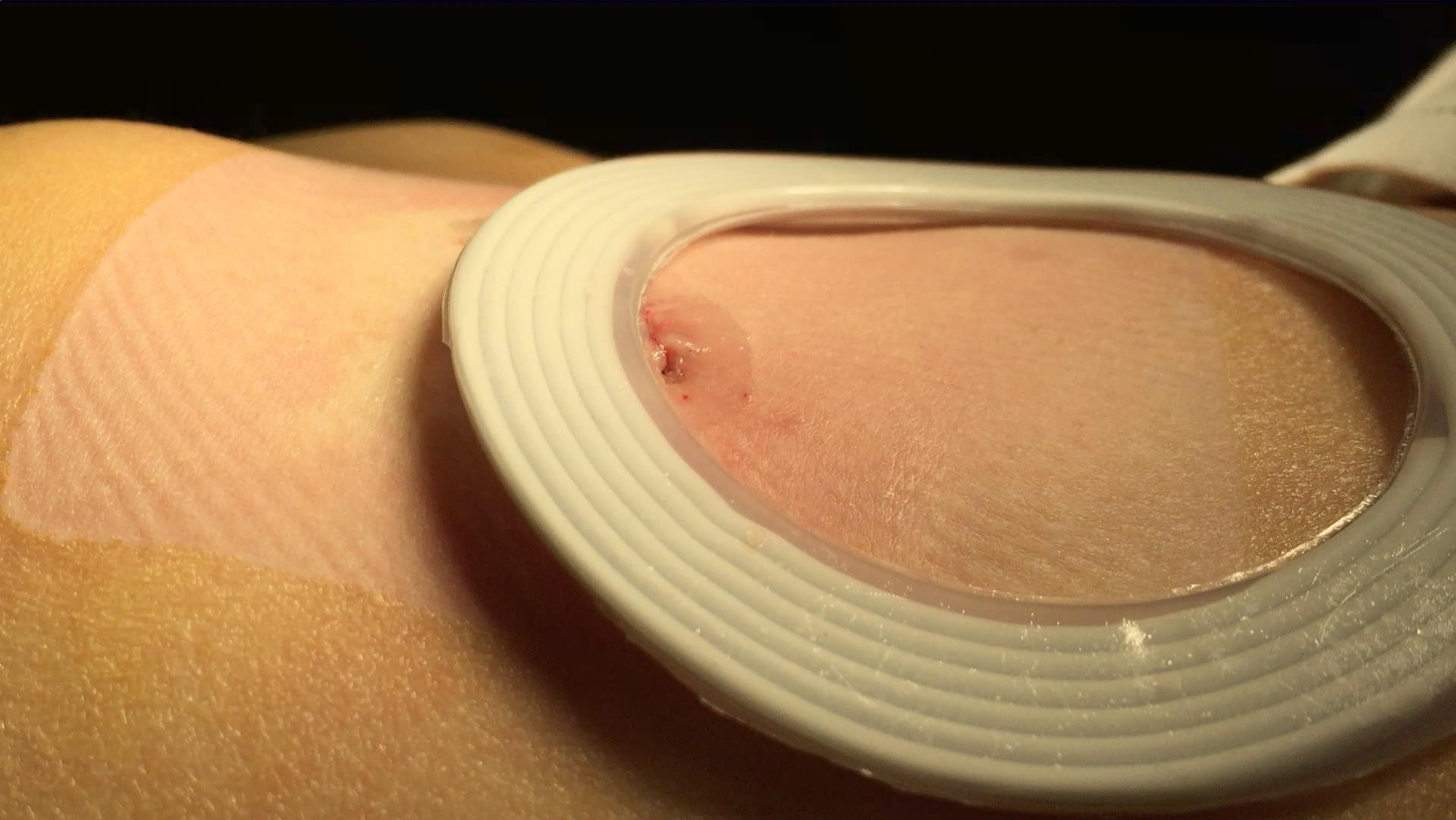
- Decubitus positioning
- 3 trochars/hemithorax
- Superior dissection of phrenic nerve
- Tunnel through diaphragm
- Subcutaneous receiver pocket











Thoracoscopic placement of phrenic nerve pacers for diaphragm pacing in congenital central hypoventilation syndrome.

Nicholson KJ¹, Nosanov LB¹, Bowen KA², Kun SS³, Perez IA³, Keens TG³, **Shin CE**⁴.

PURPOSE: Congenital central hypoventilation syndrome (CCHS), or Ondine's curse, is a rare disorder affecting central respiratory drive. Patients with this disorder fail to ventilate adequately and require lifelong ventilatory support. Diaphragm pacing is a form of ventilatory support which can improve mobility and/or remove the tracheostomy from CCHS patients. Little is known about complications and long-term outcomes of this procedure.

METHODS: A single-center retrospective review was performed of CCHS patients undergoing placement of phrenic nerve electrodes for diaphragm pacing between 2000 and 2012. Data abstracted from the medical record included operation duration, ventilation method, number of trocars required, and postoperative and pacing outcomes.

RESULTS: Charts of eighteen patients were reviewed. Mean surgical time was 3.3 ± 0.7 hours. In all cases except one, three trocars were utilized for each hemithorax, with no conversions to open procedures. Five patients (27.8%) experienced postoperative complications. The mean ICU stay was 4.3 ± 0.5 days, and the mean hospital stay is 5.7 ± 0.3 days. Eleven patients (61.1%) achieved their daily goal pacing times within the follow-up period.

CONCLUSIONS: Thoracoscopic placement of phrenic nerve electrodes for diaphragmatic pacing is a safe and effective treatment modality for CCHS. Observed complications were temporary, and the majority of patients were able to achieve pacing goals.

Operative Data

- Only one patient required placement of additional trocar
- None required conversion to open
- Operative time: 3.3 ± 0.7 hours

Post-operative care

- Mean ICU stay: 4.3 ± 0.5 days
- Mean hospital stay: 5.7 ± 0.3 days
- Short-term complications: atelectasis, pneumonia, seizure
- Long-term complications: none

CHLA Experience

- Worldwide, only a handful of centers offer thoracoscopic phrenic nerve electrode implantation for the treatment of CCHS.
- To our knowledge, this study is the largest to date to describe a single-center experience with this procedure.
- The first thoracoscopic placement of diaphragmatic pacers was described by Shaul et al in 1998 at CHLA.
- At CHLA, over 40 children with CCHS have undergone diaphragm pacing thus far.