

## Diaphragm pacing using the minimally invasive cervical approach

Don B. Headley, Antonio G. Martins, Kevin J. McShane & David A. Grossblat

To cite this article: Don B. Headley, Antonio G. Martins, Kevin J. McShane & David A. Grossblat (2021): Diaphragm pacing using the minimally invasive cervical approach, The Journal of Spinal Cord Medicine, DOI: [10.1080/10790268.2021.1940794](https://doi.org/10.1080/10790268.2021.1940794)

To link to this article: <https://doi.org/10.1080/10790268.2021.1940794>



© 2021 The Author(s). Published with license by Taylor & Francis Group, LLC



Published online: 07 Jul 2021.



Submit your article to this journal [↗](#)



View related articles [↗](#)



View Crossmark data [↗](#)

## Review

# Diaphragm pacing using the minimally invasive cervical approach

**Don B. Headley<sup>1</sup>, Antonio G. Martins<sup>2</sup>, Kevin J. McShane<sup>3</sup>, David A. Grossblat<sup>4</sup>**

<sup>1</sup>Department of Surgery, St Joseph Hospital and Medical Center, Phoenix, AZ, USA, <sup>2</sup>Avery Biomedical Devices, Commack, New York, USA, <sup>3</sup>Drexel University School of Biomedical Engineering, Philadelphia, Pennsylvania, USA, <sup>4</sup>Valley Anesthesiology Consultants, Phoenix, Arizona, USA

**Context:** The implantation of commercially available phrenic nerve/diaphragm pacers has been available for more than 40 years and has enabled thousands of patients in over 40 countries to achieve freedom from invasive mechanical ventilation.

**Objective:** The cervical approach to implantation of these pacers is described, as are the pros and cons of using this technique compared to intrathoracic and sub-diaphragmatic.

**Methods:** Study design was a retrospective review of 1,522 subjects from the Avery Biomedical Devices (ABD) database who were implanted with the Avery diaphragm pacer. Long term statistics from patients implanted with diaphragm pacers are presented as well.

**Results:** 17% of cervically placed electrodes required at least one replacement compared to 18% of electrodes placed thoracically. Devices implanted cervically show no significant difference in their longevity than those implanted using the thoracic approach (P value of 0.9382 using Two-Sample t-Test). The mean longevity for both approaches was found to be 6.4 years. The majority of electrodes implanted have never required replacement. A majority of CCHS patients were implanted using the thoracic approach and only find it necessary to use the device during sleeping hours. Most of the cervically implanted patients are found to be older at the time of implantation and implanted for diagnoses that require longer daily use of the device.

**Conclusion:** The cervical approach for the implantation of phrenic nerve/diaphragm pacers is the most minimally invasive, but underutilized, technique that allows for the use of local or monitored anesthesia, does not require entering any body cavities, and keeps incision size small.

**Keywords:** Minimally invasive, Phrenic nerve pacer

## Introduction

Upon introduction of the implantable phrenic nerve stimulator (PNS) by Dr. William Glenn in 1971, the electrodes were implanted on the phrenic nerve in the neck.<sup>1</sup> This same device could also be implanted under the nerve as it passes through the chest via an open thoracotomy.<sup>2</sup> The cervical implantation of the PNS electrode remains a common technique but has been largely ignored in the recent literature.<sup>3,4</sup>

The development of endoscopic devices has largely replaced the need for open surgical procedures.

Endoscopic approaches are now used for surgery involving the abdomen, chest, brain and sinuses, to name a few. Likewise, the use of endoscopes allows the PNS electrode to be implanted in the chest using video assisted thoracoscopic surgery (VATS) as opposed to the more invasive open thoracotomy technique and was adopted by many surgeons in the late 1990s to early 2000s.<sup>5</sup> The cervical approach to electrode placement remains the most minimally invasive technique as it does not involve entering any body cavity and can be done under local anesthesia. An update of the cervical route of implantation of diaphragm pacers and long-term statistics from patients implanted with phrenic nerve/diaphragm pacers will be presented.

Correspondence to: David A. Grossblat, Valley Anesthesiology Consultants, Phoenix, Arizona, USA. Email: david.grossblat@gmail.com

Color versions of one or more of the figures in the article can be found online at [www.tandfonline.com/yscm](http://www.tandfonline.com/yscm).

### Phrenic nerve stimulators

Currently there are three basic techniques used for implantation of phrenic nerve pacing electrodes. The cervical technique places the electrode via a small incision in the lower neck under<sup>1</sup> (Avery Biomedical Devices Inc.) or around<sup>6</sup> (Atrotech Oy) the phrenic nerve as it passes over the anterior scalene muscle. The thoracic approach uses either the open thoracotomy<sup>2</sup> or, more commonly, the less invasive VATS technique to place the Atrostim or Avery electrode in contact with the phrenic nerve as it passes over the pericardium.<sup>5</sup> The laparoscopic approach (Synapse Biomedical) places several electrodes into the abdominal aspect of the diaphragm adjacent to branches of the phrenic nerve.<sup>7</sup>

Receivers for the Atrostim and Avery devices are placed subcutaneously in the chest region and connected to the electrode via a subcutaneous wire. An external transmitter and antenna send energy and stimulus information to the passive receivers. The receivers translate radio waves into stimulating electrical pulses that are delivered to the phrenic nerve by the electrodes. The Synapse NeuRx system is connected directly to the external power source which transmits stimulating pulses to its electrodes via percutaneous wires through the abdominal skin.

In all three devices, stimulating pulses cause the diaphragm muscle to contract which produces the inhalation phase of breathing. Refer to Fig. 1 for a visualization of the stimulating pulses. The stimulation then stops, which allows the diaphragm to relax and exhalation occurs. This cycle of signals followed by no signals is repeated automatically by the pacer, producing a more natural breathing pattern.

Of the two cervically implantable devices, the Avery device is the more commonly used and will be described in detail.<sup>8</sup> The rare cervical implantation of the Atrostim device has previously been described and

differs from the implantation of the Avery device in that the quadripolar electrodes require placement on both sides of the nerve instead of just underneath.<sup>9</sup>

### Indications for cervical approach

The cervical approach for phrenic nerve stimulator implantation may be considered in patients with functioning phrenic nerves who are greater than 2 years of age and who have not had significant lower neck trauma that would place the phrenic nerve at risk during the dissection. Examples of previous neck surgery that may contraindicate the cervical approach include neck dissection and lower cervical spine surgery. A previous or current tracheotomy is not a contraindication for this surgery.

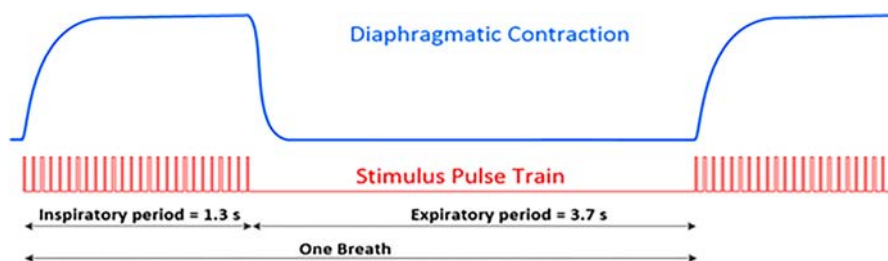
## Methods

### Surgical procedure

The incision site for the electrode is made 1–2 cm superior to the clavicle, just posterior to the sternocleidomastoid muscle and 3 cm in length parallel to the clavicle. The 2 cm horizontal incision for the receiver is along the mid clavicular line or more laterally along the mid-axillary line at the level of the 9th rib.

The incision for the electrode is carried down through the platysma muscle revealing the supraclavicular fat pad, which is bluntly dissected down to the investing layer of deep cervical fascia. Immediately deep to this fascia lies the phrenic nerve running in a lateral to medial direction and superficial to the anterior scalene muscle. Positive identification of the phrenic nerve is achieved with a disposable nerve stimulator revealing diaphragm movement.

The site for the tunnel under the phrenic nerve for placement of the electrode is to be low in the neck where stimulation of the phrenic nerve does not result in movement of the patient's arm or shoulder. A 0.5 cm tunnel is made between the phrenic nerve and the underlying



**Figure 1** Stimulus pulse train transmitted from the Diaphragm Pacemaker in red and its corresponding diaphragmatic contraction in blue. When stimulation is active, the diaphragm contracts causing the patient to inhale. The stimulation stops, relaxing the diaphragm and causing the patient to exhale. This figure shows a stimulation signal with individual pulses that have a width of 150  $\mu$ S and a period of 50 ms between each pulse. The pulse train lasts for 1.3 s (inspiration) and pulses begin again after 3.7 s (expiration). All parameters of the pulse train are customizable.

anterior scalene muscle. The electrode is carefully placed under the phrenic nerve (refer to Fig. 2).

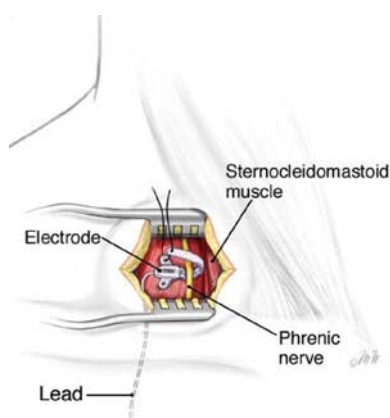
The incision for the receiver is made and a pocket developed approximately 1 cm deep to the skin surface where the receiver is placed with the anode disc facing down and the receiver is connected to the electrode wire. The sterile antenna is placed over the receiver and the implant is tested using the external pulse generator. The amplitude of the signal is increased until a diaphragmatic contraction is observed. The amplitude is then increased further to ensure there is no adjacent muscle or arm movement, an indication of unwanted brachial plexus stimulation.

When adequate stimulation of the diaphragm is achieved, the electrode is sutured to the anterior scalene muscle with a 4-0 Prolene™ suture and a small loop is made in the proximal electrode wire. The electrode and receiver are then disconnected.

A large ventricular – peritoneal shunt tunneler is passed subcutaneously to connect the incision sites and pull the electrode wire through so it may be connected to the receiver. After the system is tested and the proper stimulus to the nerve is determined, the receiver can be sutured to the deep tissue inside the subcutaneous pocket to prevent possible migration. The incisions are closed in layers after a small loop of the electrode wire is made in the neck and chest incision site to prevent traction and allow for patient growth. Figure 3 shows an approximation of the placement of the electrode and receiver respectively.

#### Statistics from company database

Information on patients implanted with the Avery Diaphragm Pacemaker was collected using Avery Biomedical Devices Inc. (ABD) digital database and user surveys accessed on January 1st 2020.



**Figure 2** Electrode placement and suturing in cervical approach.

Information from the ABD database includes surgical approach used for initial and any revision implantations, age of patient during implantation, number of years using implants, and rationale for revision implantations ABD conducts a survey of all active patients in the form of a questionnaire every 2 years. Information from the bi-annual user surveys includes hours per day using the pacemaker and tracheostomy status.

#### Results

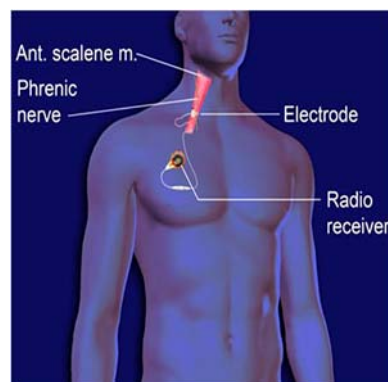
A total of 1522 patients were identified through ABD patient files dating back to 1970. Of these patients 490 were initially implanted cervically, 583 were initially implanted thoracically. The remaining 449 patient's initial implant locations could not be determined. Including revision surgeries, the total number of devices implanted was 3478.

#### Surgical approach used per decade

In the 1970s, the Avery Diaphragm Pacemaker was implanted primarily in spinal cord injury patients. The 1980s saw an increase in diversity of diagnoses treated, including central sleep apnea, congenital central hypoventilation syndrome, diaphragm paralysis and others.<sup>10</sup> During the late 1990s and early 2000s, VATS became a breakthrough method for implanting the Avery diaphragm pacemaker with Children's Hospital of Los Angeles popularizing the approach.<sup>5</sup> The Avery data reflects the popularity of VATS in the 2000s. Figure 4 provides a visual of these trends.

#### Surgical approach used based on age of patient

Thoracic placement of the electrodes is more common in pediatric cases. The youngest patient implanted using the thoracic approach was 57 days old; the youngest patient implanted using the cervical approach was 7 months old. According to the database statistics, most surgeons using the cervical route wait until the child is at least 2 years of age before implantation.



**Figure 3** Visualization of placement of electrode and receiver.

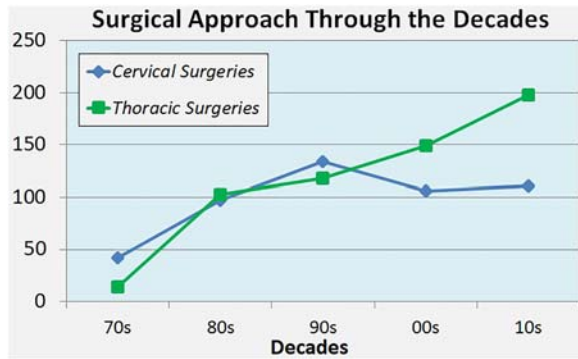


Figure 4 Surgeries performed per decade separated by approach.

By the time patients reach early adulthood, both surgical approaches are more evenly utilized. Refer to Fig. 5 below for a breakdown of patient age during implantation and approach used.

*Years patients spent pacing*

A total of 3 active patients have been pacing for over 40 years. Two deceased patients were pacing for over 40 years before their deaths. A total of 33 active patients have been using the Avery Diaphragm pacer for over 30 years with an additional 8 patients who paced for over 30 years before death (Fig. 6).

*Revision surgeries*

Since implantation of the current version of the implanted receiver (I-110) in 1990, 854 patients have been implanted. 682 of these patients have never required a revision surgery. 24 of these patients have used their original implants for over 25 years.

One hundred and seventy-two patients have required revision surgeries since implementation of the I-110 receiver in 1990 according to the company database.

The average time spent in between revision surgeries was approximately 6.5 years. The median was 5 and the

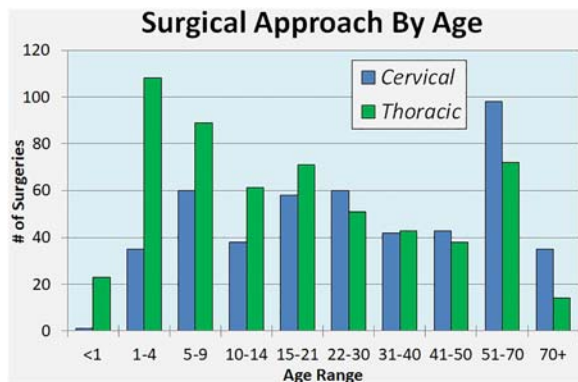


Figure 5 Patient age during initial implantation, separated by approach.

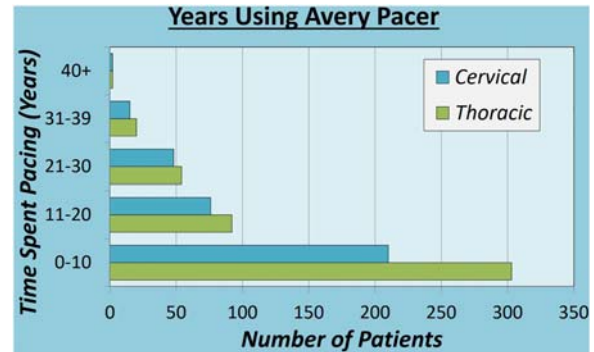


Figure 6 Number of years spent using the Diaphragm Pacer.

Standard Deviation was 6.29. Table 1 shows a breakdown of these patients separated by approach. Years in between revision surgeries for these patients is a good indicator for implant longevity. Statistical analysis of this data showed no significant difference in the amount of time implants last in cervical patients vs. thoracic. Refer to Table 1 for a breakdown of the ratios for each revision.

Next, an analysis of electrode revisions was conducted. This analysis ignored any revision in which only the receivers were replaced. Table 2 shows a summary of the revision data collected for electrode replacements only. 17% of cervical cases required at least one revision of the electrode compared to 18% of thoracic cases. Data showed that in patients initially implanted cervically, 45% of electrode revisions involved moving the electrode placement to the chest compared to 10% of patients whose implants were moved from the chest to the neck. The decision as to where to replace an electrode was based on several factors including changing the electrode placement from the cervical position to the thoracic position (or visa versa) to minimize chances of nerve damage by avoiding scar tissue from previous surgery, infection at the current site of electrode placement and availability of surgeon experienced with the particular approach. Additionally, there is a greater area of accessible phrenic nerve in the chest for placement of the electrode and more thoracic surgeons currently practicing thoracic placement as opposed to cervical.

Table 1 Longevity of implants separated by surgical approach.

Initial Surgical Approach	Mean (SD)	Median
All	6.5 (6.2)	5
Cervical	6.4 (6.8)	4
Thoracic	6.4 (5.7)	5

Note: SD, Standard Deviation; calculated P value was 0.9328 using a Two-Sample t-Test.

**Table 2** Revision data of all electrode replacements.

Initial Surgical Approach	# of Patients Who Required Electrode Revision(s)	Total # of Electrode Revisions	Change of Electrode Location	No Change in Electrode Location
Cervical	66 out of 380 total patients	82	37 Cervical to Thoracic	25
Thoracic	95 out of 518 total patients	113	10 Thoracic to Cervical	77
One Side Cervical and One Side Thoracic	7 out of 9 total patients	14	–	–
Total	169 out of 962 (47 patients w/ Unknown Electrode locations)	209	47	–

*No Report/No Problem Found:* In 18% of the revision surgeries identified, explanted components were found to have no defects and passed all electrical testing.

*Surgical Placement of Implants:* Placement of electrode and receivers during a patient's initial surgery can occasionally impact their pacing moving forward and accounted for 14% of revision surgeries. This includes but is not limited to the creation of a subcutaneous pocket that is too large and may allow migration of the implant, as well as the improper suturing of the electrode resulting in a loss of contact with the nerve.

*Intermittent:* Loss of stimulation occurred in 13% of revision cases. This is most common in patients who have been using the same implants for longer than the expected service life and require a replacement.

*Insulation Damage:* 12% of the identified revision surgeries were due to damage in the insulation of the implanted wire. Damage to the insulation of the wire may result in current leakage and cause a shocking sensation. This damage may occur during surgical procedures near the site of the electrode.

*Damage to Wire:* 9% of revision surgeries had a damaged wire as their cause. One case in which this occurred was a result an accidental cut to the electrode wire during a receiver replacement surgery. Broken wires can be a total severing of the wire and insulation or damage to the wire inside intact insulation and require replacement.

*Calcification of Anode:* 8% of revisions were the result of a deposition of calcium in scar tissue surrounding implants. Calcification occurs specifically at the site of

the anode plate and causes the anode to lose electrical contact.

*Accidental Damage – Sports:* 6% of revisions were due to damage to the implants that occurred during physical therapy, sports related injuries, and impact with the implanted receivers.

*Accidental Damage – Medical Treatment:* 5% of revisions consisted of implants that were damaged during patient treatment unrelated to the function of the pacers. Any subsequent surgeries patients have, proper precautions should be taken to ensure their implants are not accidentally cut or impacted.

*Infection After Surgery:* 5% of revisions were required due to an infection the patient received that spread to the implants. Any infection that spreads to the implants results in explantation of the equipment, followed by treatment and subsequent reimplantation of a new system on that side.

*Twiddler:* 4% of revision surgeries were required as a result of twisted receiver wires and backwards facing anode plates. Patients who play or nervously fidget with their subcutaneously placed receivers are known as “twiddlers.” It is a relatively uncommon complication mainly affecting pediatric users of the device.<sup>11,12</sup> Refer to Fig. 7 for a receiver that has been twiddled. All receiver replacements can be done by exploring the subcutaneous pocket. No incisions in the neck or chest are needed (Fig. 8).

*Patient Growth:* The implants may also be affected by growth of the patient. This accounted for 5% of revision surgeries. Growth includes weight gain, breast development during puberty, and changes in height. Weight gain and breast development may affect the antenna-receiver coupling and requires a simple repositioning of the current receivers.

#### Company patient survey

One hundred and eleven responses were collected from active patients in 2018. Two key pieces of data collected include the number of patients who have had a tracheostomy removal and the time in hours per day patients spend pacing.

#### Tracheostomy

Seventy-six percent of questionnaire responders had a tracheostomy prior to implantation with 24% never requiring one. Roughly one third of patients with a tracheostomy prior to implantation choose to have them removed following implantation.<sup>13</sup>

#### Patient reported daily amount of time spent pacing

Fifty-seven percent of respondents reported they pace for 7–12 h per day, primarily while sleeping. Central Sleep Apnea and Congenital Central Hypoventilation

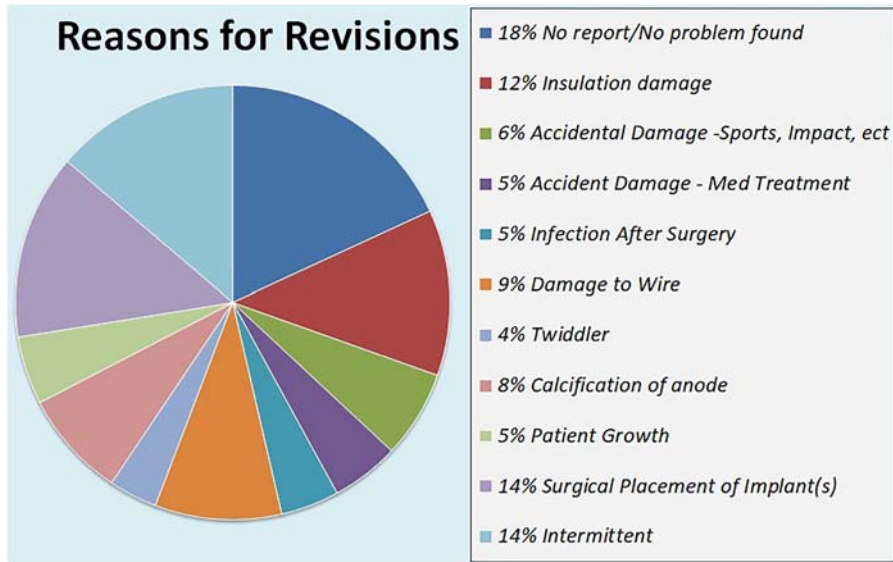


Figure 7 Revision rationales for cervically implanted patients by percentage.

Syndrome were the most common diagnoses for patients in this category. 14% of respondents reported they pace for 13–15 h per day. An additional 13% of patients reported daily pacing of 16–20 h. 16% of respondents reported “24/7” use of the pacer.

Although many patients in this category have diagnoses that may require 24 h ventilatory support

(Spinal Cord Injury, Diaphragm Paralysis), some patients prefer to pace while awake/active and switch to mechanical ventilation while sleeping. 12 hours per day pacing is often sufficient for CCHS patients and quadriplegics who use the pacer continuously during waking hours and utilize ventilator support during sleep.



Figure 8 Explanted receiver from revision surgery of a “twiddler” (Note the entangled wire).

### Discussion

The purpose of this paper is to describe the cervical technique of implanting PNS devices, compare it to other minimally invasive implantation techniques and provide data from the Avery Biomedical Devices databank on nearly 3500 implantations of the Avery device over the past 38 years. Minimally invasive techniques, besides having smaller incisions, minimize patient perioperative morbidity. Operative time is similar (1-2 hrs) for all commonly employed PNS implantation techniques (personal communication).

The laparoscopic approach, utilized with the Synapse device, is performed under general anesthesia. It involves several punctures through the abdominal wall that allow introduction of the instrumentation enabling the placement of four electrodes into the diaphragm adjacent to branches of the phrenic nerve. Stimulation of the phrenic nerve is achieved through electrode wires exiting through the skin over the abdomen and connected directly to the external pulse generator.

The VATS approach, utilized with the Atrotech and Avery devices, is also performed under general anesthesia and uses a double lumen instead of a single lumen

endotracheal tube. It involves several punctures through the chest wall allowing introduction of the instrumentation enabling the placement of an electrode around (Atrotech device) or under (Avery device) the phrenic nerve as it passes along the pericardium. Stimulation of the phrenic nerve is achieved through electrode wires attached to a subcutaneously placed receiver that receives its input via radiofrequency waves from an external pulse generator attached to an antenna placed on the skin over the receiver.

The cervical approach, utilized with the Atrotech and Avery device, can be performed with, or in some cases, without general anesthesia. In the cervical technique of implantation, the nerve is accessed through a small incision in the lower neck. The electrode is implanted on the phrenic nerve as it courses through the neck superficial to the anterior scalene muscle. The electrode wire is then tunneled subcutaneously and connected to the implanted receiver as with the VATS technique thus allowing stimulation of the nerve without having entered any body cavity.

A discussion and plan for airway management between the surgeon and anesthesiologist should take place prior to the case. The baseline respiratory function of the patient is an important consideration. Any surgical procedure can be performed utilizing one or a combination of anesthetic techniques including general, regional, and monitored anesthesia care (MAC). Most patients are intubated for procedures done under general anesthesia after being induced with either inhalation or intravenous anesthesia. A natural airway can be utilized if sedation or MAC is planned in a patient with adequate respiratory function and no identified risk factors for aspiration.

If a cuffed tracheostomy tube is present, it can be utilized for the laparoscopic technique. A double lumen endotracheal tube is typically used when employing the VATS technique. When using the cervical technique, the tracheostomy tube is removed, the tracheostomy site is then covered with an occlusive dressing such as Tegaderm™ or Opsite™, in order to maintain an adequate seal for positive pressure ventilation and isolate the tracheostomy site from the surgical field. A laryngeal mask airway could also be placed if the patient was deemed an appropriate candidate and able to maintain spontaneous respiration. At the completion of the case, most patients meet extubation criteria and are taken to the recovery room without an airway adjunct.

Most intra-abdominal surgeries are performed with general endotracheal anesthesia and positive pressure ventilation.<sup>13</sup> This allows the use of neuromuscular blockade and relaxes the abdominal musculature and diaphragm resulting in more favorable surgical conditions. The use of neuromuscular blockade and

subsequent reversal adds to the polypharmacy of the anesthetic and increases the risk of allergic reaction<sup>14</sup> and the potential for variable<sup>15</sup> and residual weakness.<sup>16,17</sup> Insufflation of the abdomen with carbon dioxide has potential hemodynamic and pulmonary consequences.<sup>13,18</sup> Most intrathoracic surgeries are also performed with general endotracheal anesthesia.<sup>19</sup> An arterial catheter is commonly placed in addition to standard American Society of Anesthesia monitors in order to achieve real time hemodynamic monitoring due to the proximity of the heart and great vessels in the thorax. At times, lung isolation would facilitate a more favorable surgical field and a double lumen endotracheal tube or bronchial blocker is utilized.<sup>20</sup> These techniques can be technically challenging and increase the risks of airway trauma as well as pulmonary complications including atelectasis, pneumothorax, hypoxemia, and barotrauma.<sup>20,21</sup> Therefore, in a patient without aspiration precautions and normal spontaneous respiratory function, sedation can be utilized in the cervical approach as the surgical stimulation is less intense when the abdomen and thorax are not entered.

Anesthesia techniques are simpler and less invasive with the cervical technique. In select cases, where the patient is able to breathe spontaneously, general anesthesia may be avoided and only monitored anesthesia employed. The cervical technique may allow the patient to be discharged without overnight observation or hospital admission.

There are several factors to consider when choosing which implantation technique to use. The thoracic and abdominal approaches are more commonly used by general and thoracic surgeons. The cervical route of implantation is preferred by neurosurgeons and otolaryngologists.

The thoracic placement of electrodes is done more frequently in children than adults. This trend is likely due to the small size of the patient in early childhood. Anatomically, it may be more advantageous to implant the electrode through the chest cavity in small children than in the neck because the proximity of the brachial plexus to the phrenic nerve may result in simultaneous stimulation of the brachial plexus with phrenic nerve stimulation. In geriatric patients, the cervical approach may be favored due to the increased sensitivity geriatric patients have to anesthetic agents.<sup>22</sup> Implanting the Avery Diaphragm Pacemaker via the cervical approach offers the possible use of local or monitored anesthesia.

Potential complications differ with the selected surgical technique. A complication unique to PNS implantation is injury to the phrenic nerve. There have been six documented cases of phrenic nerve injury using



the ABD device in 3,478 implants over the past 38 years (less than 0.2%). All cases were the result of surgical manipulation of the nerve. One of these cases occurred using the cervically implanted electrode. In five of the six cases the nerve function recovered.

Hypercapnia or capnothorax may be noted during or after laparoscopic placement of PNS and may require intraoperative modulation of the surgery or anesthesia; or postoperative thoracentesis/chest tube placement. Persistent pneumothorax is a possible complication after VATS that may require placement of a chest tube and extending the postoperative recovery time. The cervical implantation technique avoids possible complications of pneumothorax, capnothorax or hypercapnia by not having to enter the thorax or abdomen while placing a PNS. In addition, no specialized instrumentation, such as laparoscopes, is needed and, in some cases, the surgery may be done without general anesthesia. The cervical approach to PNS implantation is considered minimally invasive not just due to the small size of the incisions needed but also the reduced perioperative morbidity associated with the technique.

## Conclusion

The cervical approach to PNS placement is a minimally invasive technique offering unique advantages over other methods of implantation. The technique has been successfully used in hundreds of patients over the past 38 years. It does not involve entering any body cavity and can be done under local anesthesia. This approach should be considered in appropriate patients primarily for its unique ability to reduce perioperative morbidity. It has been shown that patients who undergo PNS placement have used them daily for 20–30 years, some of whom pace for 24 h a day. Most of the CCHS patients were implanted using the thoracic approach and only find it necessary to use the device during sleeping hours. Most of the cervically implanted patients were implanted for diagnoses other than CCHS and require longer daily use of the device. Additionally, we found no statistically significant difference in the longevity of the implanted device based on the surgical approach used for implantation. No difference was found between the cervical or thoracic approaches in regard to the need for subsequent electrode revisions.

## Acknowledgements

Dilys Gore, PhD is a biomedical engineer at Avery Biomedical Devices and assisted with the data analysis.

## Disclaimer statements

**Contributors** None.

**Funding** None.

**Conflicts of interest** Don Headley, MD is a clinical consultant for Avery Biomedical Devices. David Grossblat, MD reports no potential competing interest. Tony Martins and Kevin McShane declare employment for a manufacturer of Diaphragm Pacers.

## References

- 1 Glenn WWL. Diaphragm pacing: present status. *Pacing Clin Electrophysiol* 1978 Jul-Sep;1(3):357–70.
- 2 Glenn WWL, Hogan JF, Phelps ML. Ventilatory support of the quadriplegic patient with respiratory paralysis by diaphragm pacing. *Surg Clin North Am* 1980;60(5):1055–78.
- 3 Le Pimpec-Barthes F, Legras A, Arame A, Pricopi C, Boucherie J-C, Badia A, et al. Diaphragm pacing: the state of the art. *J Thorac Dis* 2016 Apr;8(4):S376–86.
- 4 DiMarco A. Diaphragm pacing. *Clin Chest Med* 2018;39:459–71.
- 5 Shaul DB, Danielson PD, McCom JG, Keens TG. Thoracoscopic placement of phrenic nerve electrodes for diaphragmatic pacing in children. *J Pediatr Surg* 2002 Jul;37(7):974–78.
- 6 Talonen P, Baer G, Huhti M, Hakkinen V. Modulation of muscle force by recruitment and firing rate during multipolar nerve stimulation. in: Life support systems – Proceedings, Annual Meeting ESAO, Athens Greece 1985;3(1):316–20.
- 7 DiMarco AF, Onders RP, Kowalski KE, Miller ME, Ferek S, Mortimer JT. Phrenic nerve pacing in a tetraplegic patient via intramuscular diaphragm electrodes. *Am J Respir Crit Care Med* 2002;166:1604–6.
- 8 Weese-Mayer DE, Silvestri JM, Kenny AS, Ilbawi MN, Hauptman SA, Lipton JW, et al. Diaphragm pacing with a quadriplegic phrenic nerve electrode: an international study. *Pacing Clin Electrophysiol* 1996;19:1311–9.
- 9 Le Pimpec-Barthes F, Gonzalez-Bermejo J, Hubsch J-P, Duguet A, Morélot-Panzini C, Riquet M, et al. Intrathoracic phrenic pacing: a 10-year experience in France. *J Thorac Cardiovasc Surg* 2011;142:378–83.
- 10 Glenn WWL, Phelps ML, Elefterleades JA, Dentz B, Hogan JF. Twenty years of experience in phrenic nerve stimulation to pace the diaphragm. *Pacing Clin Electrophysiol* 1986;9(6):780–4.
- 11 Fitzgerald D, Davis GM, Gottesman R, Fecteau A, Guttman F. Diaphragmatic pacemaker failure in congenital central hypoventilation syndrome: a tale of two twiddlers. *Pediatr Pulmonol* 1996;22:319–21.
- 12 Diep B, Wang A, Kun S, McComb JG, Shaul DB, Shin CE, et al. Diaphragm pacing without tracheostomy in congenital central hypoventilation syndrome patients. *Respiration* 2015;89:534–8. Epub 2015 APR 25.
- 13 Andersson LE, Baath M, Thorne A, Aspelin P, Odeberg-Werner S. Effect of carbon dioxide pneumoperitoneum on development of atelectasis during anesthesia, examined by spiral computed tomography. *Anesthesiology* 2005;102(2):293–9.
- 14 Mertes PM, Laxenaire M-C, Alla F. Anaphylactic and anaphylactoid reactions occurring during anesthesia in 1999–2000. *Anesthesiology* 2003;99:536–45.
- 15 Arain SR, Kern S, Ficke DJ, Ebert TJ. Variability of duration of action of neuromuscular blocking drugs in elderly patients. *Acta Anaesthesiol Scand* 2005;49:312–5.
- 16 Naguib M, Brull SJ. Sugammadex: a novel selective relaxant binding agent. *Expert Rev Clin Pharmacol* 2009;2:37–53.
- 17 Kampe S, Krombach JW, Diefenbach C. Muscle relaxants. *Best Pract Res Clin Anaesthesiol* 2003;17:137–46.
- 18 Kendall AP, Bhatt S, Oh TE. Pulmonary consequences of carbon dioxide insufflation for laparoscopic cholecystectomies. *Anaesthesia* 1995;50:286–9.
- 19 Slinger PD, Campos J. Anesthesia for thoracic procedures. In: Miller RD, (ed.) *Miller's anesthesia*. 9th ed. New York: Churchill Livingstone; 2010. p. 1833–41.

- 20 Nagendran J, Stewart K, Hoskinson M, Archer SL. An anesthesiologist's guide to hypoxic pulmonary vasoconstriction: implications for managing single-lung anesthesia and atelectasis. *Curr Opin Anaesthesiol* 2006;19:34–43.
- 21 Higgs TL. Post thoracotomy complications. In: Kaplan JA, Slinger PD, (eds.) *Thoracic anesthesia*. 3rd ed. Philadelphia: Churchill Livingstone; 2003. p. 159–73.
- 22 Kanonidou Z, Karystianou G. Anesthesia for the elderly. *Hippokratia* 2007;11(4):175–7.